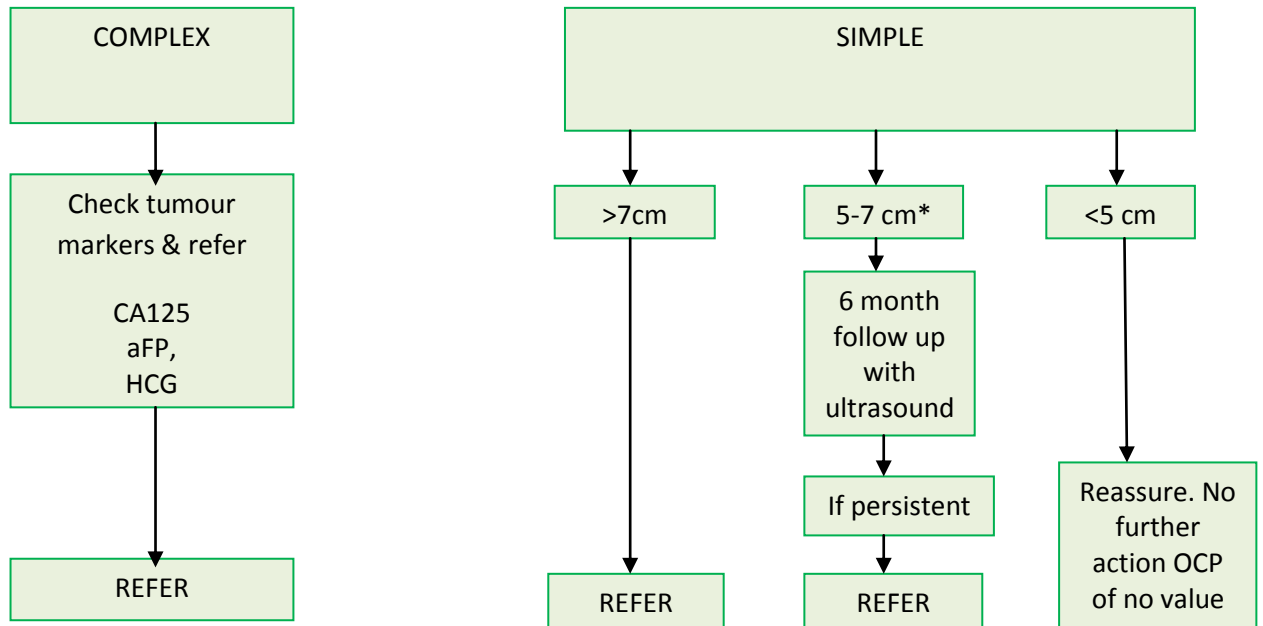


## Premenopausal Ovarian cyst on Ultrasound (>3cm)



Ultrasound features that make a cyst complex:

- Solid components
- Septae

\*If symptomatic, refer & provide leaflet found at:

[http://www.rcog.org.uk/files/rcog-corp/PI\\_Ovarian\\_cysts\\_before\\_the\\_menopause\\_\(2\).pdf](http://www.rcog.org.uk/files/rcog-corp/PI_Ovarian_cysts_before_the_menopause_(2).pdf)

Lead Consultant: Mr Faraj  
Lead GP: Jason Page  
Date Approved: 18 December 2013  
Last Reviewed: 14 January 2020  
Review Date: January 2023